

F. Tavani
R.A. Zimmerman
R.R. Clancy
D.J. Licht
W.T. Mahle

Incidental intracranial hemorrhage after uncomplicated birth: MRI before and after neonatal heart surgery

Received: 7 November 2002
Accepted: 6 December 2002
Published online: 15 March 2003
© Springer-Verlag 2003

F. Tavani · R.A. Zimmerman (✉)
Neuroradiology Department,
The Children's Hospital of Philadelphia,
34th Street & Civic Center Blvd,
Philadelphia, PA 19104, USA
E-mail: zimmerman@email.chop.edu
Tel.: +1-215-5901030
Fax: +1-215-5901345

R.R. Clancy · D.J. Licht
Department of Neurology,
The Children's Hospital of Philadelphia,
34th Street & Civic Center Blvd,
Philadelphia, PA 19104, USA

W.T. Mahle
Children's Heart Hospital,
Atlanta, GA 30341, USA

Abstract We investigated the prevalence of intracranial hemorrhage (ICH) before and after neonatal heart surgery. We carried out pre- and postoperative MRI looking for brain lesions in 24 full-term newborns with known congenital heart disease. They underwent heart surgery with cardiopulmonary bypass (CPB), usually with deep hypothermic circulatory arrest (DHCA). The first MRI was 1–22 days after birth. There were 21 children born after uncomplicated vaginal delivery and three delivered by cesarean section (CS). ICH was seen in 13 (62%) of the vaginal delivery group but in none of the CS group. We saw subdural bleeding along the inferior surface of the tentorium in 11 (52%) and supratentorially in six (29%) of the 21 children with ICH. Small

hemorrhages were present in the choroid plexus in seven (33%), in the parenchyma in one (5%) and in the occipital horn in one (5%). There were 26 foci of bleeding in these 21 patients (1.2 per patient). None was judged by formal neurologic examination to be symptomatic from the hemorrhage. Follow-up MRI after cardiac surgery was obtained in 23 children, showing 37 foci of ICH (1.6 per patient), but all appeared asymptomatic. Postoperatively, ICH had increased in 10 children (43%), was unchanged in seven (30%) and was less extensive in six (26%).

Keywords Congenital heart disease · Surgery · Intracranial hemorrhage · Magnetic resonance imaging

Introduction

Intracranial hemorrhage (ICH) at birth is described following vaginal delivery complicated by the use of forceps or vacuum extraction. Other factors that may increase the risk of trauma include a large head, precipitous or prolonged labor, breech presentation, and cephalopelvic disproportion [1, 2]. Our purpose was to investigate the prevalence of incidental intracranial hemorrhage in asymptomatic full-term neonates with known congenital heart disease (CHD) born by uncomplicated vaginal delivery or cesarean section. We also describe changes in ICH after heart surgery.

The results of the Children's Hospital of Philadelphia neurocardiac protection trial have been reported in a large group of infants with CHD [3]. Postoperative MRI demonstrated periventricular leukomalacia (PVL) in more than half of the survivors of neonatal cardiac surgery, but it was not known whether PVL might have predated surgery. The present study was therefore conducted on newborns with CHD, with pre- and postoperative MRI, to compare them for PVL. We emphasize the appearance of preoperative brain hemorrhage after uncomplicated delivery and the typical range of changes after cardiac surgery.

Table 1 Patient characteristics and preoperative clinical and MRI examinations

Patient, sex	Birth weight (kg)	Estimated gestational age (weeks)	Apgar score at 1 min	Apgar score at 5 min	Delivery	Cardiac Defect	Mental status	Occipitofrontal circumference (cm)
1,M	2.5	40.0	8	9	Vaginal	Double-outlet right ventricle, mitral atresia	Lethargic	35.5
2,F	3.1	39.0	8	9	Vaginal	Hypoplastic left heart syndrome	N/A ^a	35.5
3,F	3.7	40.0	9	9	Vaginal	Single left ventricle	Lethargic	35.75
4,F	4.0	40.0	8	9	Vaginal	Unbalanced common atrioventricular canal	N/A	N/A
5,M	3.4	40.3	8	9	Vaginal	Double-inlet left ventricle	N/A	36.25
6,M	2.9	38.0	9	9	Vaginal	Hypoplastic left heart syndrome	Normal	33.5
7,M	3.2	39.1	9	9	Vaginal	Hypoplastic left heart syndrome	N/A	N/A
8,M	3.8	40.8	7	8	Vaginal	Hypoplastic left heart syndrome	Lethargic	33.75
9,F	3.4	34.5	8	9	Vaginal	Ventriculoseptal defect	Normal	34.75
10,M	3.8	39.0	9	9	Cesarean	Hypoplastic left heart syndrome	Normal	35.75
11,F	2.2	36.0	9	9	Vaginal	Ventriculoseptal defect	Normal	33.0
12, M	2.7	36.0	8	9	Cesarean	Transposition of great vessels	Normal	33.0
13, M	3.2	39.4	8	9	Vaginal	Hypoplastic left heart syndrome	Normal	34.75
14, F	3.6	39.4	7	9	Vaginal	Hypoplastic left heart syndrome	Normal	35.5
15, M	2.9	39.4	9	9	Vaginal	Ventriculoseptal defect + aortic atresia	Normal	33.75
16, M	2.1	38.6	8	9	Vaginal	Transposition of great vessels	N/A	N/A
17, M	4.7	39.7	8	9	Vaginal	Ventriculoseptal defect + aortic atresia	Normal	35.75
18, M	4.6	35.0	8	9	Vaginal	Transposition of great vessels	Normal	35.25
19,M	4.5	41.0	8	9	Vaginal	Hypoplastic left heart syndrome	N/A	36.5
20,M	2.8	39.0	8	8	Vaginal	Truncus arteriosus	Normal	33.25
21,F	3.7	40.0	8	9	Vaginal	Pulmonary stenosis	Normal	33.25
22,F	2.8	37.0	9	9	Cesarean	Transposition of great vessels	Normal	34.0
23,M	3.7	40.0	7	8	Vaginal	Transposition of great vessels	Normal	36.0
24,M	3.2	39.6	8	9	Vaginal	Ventriculoseptal defect	N/A	36.0
Totals								

^anot available or performed

Material and methods

We studied full-term neonates referred for management of CHD. The parents of eligible children gave written permission and the protocol was approved by the institutional review board. Infants enrolled were examined for level of consciousness and muscle tone before and after surgery by pediatric neurologists (R.C., D.L.). They were transported to the imaging suite by cardiac anesthesiologists and then taken directly to the operating room for their heart surgery. We planned to obtain follow-up MRI within 2 weeks of surgery in the survivors.

Images were obtained at 1.5 tesla, with the following sequences: sagittal T1-weighted spin-echo, axial and coronal T2-weighted fast spin-echo, axial T2*-weighted gradient-echo and

axial diffusion-weighted images; we also performed MR spectroscopy on the basal ganglia to look for lactate. All images were reviewed for ICH by two neuroradiologists (F.T., R.Z.).

Results

Maternal age varied between 19 and 31 years. The 24 singleton infants were 16 boys and eight girls, gestational ages 37–41 weeks, mean birth weight 3360 g, range 2500–4655 g (Table 1). There were 21 born by uncomplicated vaginal delivery with cephalic presentation and three following cesarean section.

Tone in arms	Tone in legs	Age at MRI (days)	Number of hemorrhagic lesions	Tentorial subdural hematoma	Supratentorial subdural hematoma	Parenchymal hematoma	Choroid plexus bleed	Intraventricular bleed
Decreased	Increased	11	2	1	1			
N/A	N/A	1	0					
Decreased	Decreased	3	2	1			1	
N/A	N/A	4	2	1			1	
N/A	N/A	15	3	1	1		1	
Normal	Normal	4	0					
N/A	N/A	2	2	1	1			
Increased	Increased	2	2	1	1			
Normal	Normal	22	0					
Normal	Normal	5	0					
Increased	Decreased	4	2	1			1	
Normal	Normal	5	0					
Normal	Normal	4	3	1			1	1
Normal	Normal	4	2	1			1	
Normal	Normal	5	0					
N/A	N/A	3	1			1		
Normal	Normal	7	2	1	1			
Increased	Decreased	3	0					
N/A	N/A	8	2	1	1			
Normal	Normal	10	0					
Normal	Decreased	2	0					
Normal	Normal	4	0					
Normal	Decreased	4	1				1	
N/A	N/A	3	0					
			26	11	6	1	7	1

There were 14 patients with a functional single ventricle, including 12 with the hypoplastic left heart syndrome, three with transposition of the great vessels, four with ventriculoseptal defect and aortic arch hypoplasia, and one each with truncus arteriosus, interrupted aortic arch, and severe pulmonary stenosis. Cardiopulmonary bypass (CPB) was employed in all 24 patients and deep hypothermic circulatory arrest (DHCA) in 21. One patient died after surgery, but not before the postoperative MRI.

The first MRI study was performed between days 1 and 22 (mean 9.3 days), and follow up on 22 children

between 5 and 12 days (mean 7 days) after surgery, and on one child 84 days after surgery. One survivor was lost to MRI follow-up.

Of the 21 infants delivered vaginally, 13 (62%) had ICH (Table 1); no bleeding was seen in those delivered operatively. The most common form of bleeding was subdural hemorrhage along the inferior aspect of the tentorium, seen in 11 (52%) of 21 (Fig. 1A). A small amount of supratentorial hemorrhage occurred in the subdural space, along the tentorium and falx or more laterally (Fig. 1B) in six (29%) and within the choroid plexuses in seven (33%) (Fig. 2B). There was a small

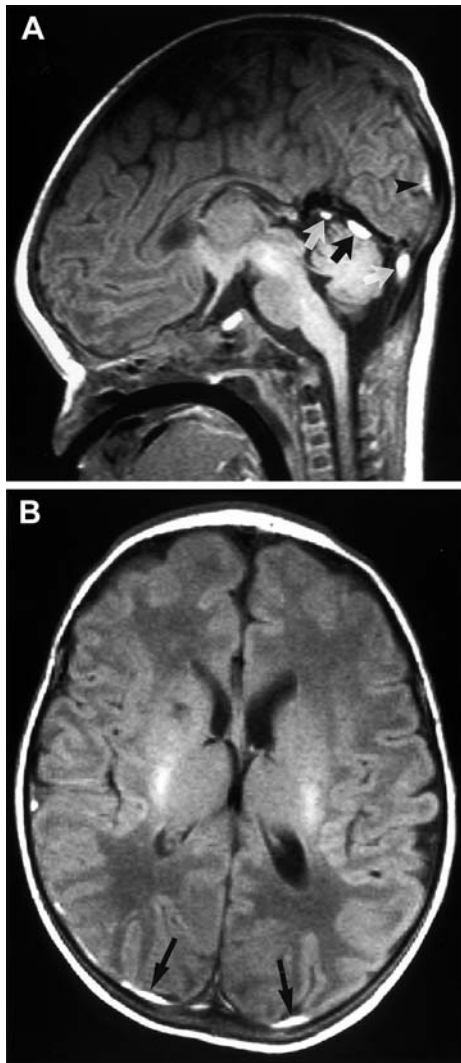


Fig. 1A, B Patient 5: subdural hemorrhage. **A** Sagittal T1-weighted image shows infratentorial high-signal subdural blood (*arrows*) and a small supratentorial hemorrhage (*arrowhead*). **B** Axial T1-weighted image shows bilateral small supratentorial subdural hematomas (*arrows*), larger on the right

focus of parenchymal blood in one (5%) and a small amount of hemorrhage in the occipital horns in another (5%) (Fig. 2). All subdural hemorrhage was seen as high signal on T1-weighted images (Fig. 1). Choroid plexus hemorrhage was best seen on T2*-weighted gradient-echo images (Fig. 2B). No mass effect on the brain was observed.

The number of foci of ICH in individual patients ranged from none to three, average 1.2 per patient (26 foci of ICH in 21 patients). On formal neurologic examination of 17 infants, there was judged to be no relationship between the ICH and any neurological deficit.

Postoperative studies were performed on 23 patients (Table 2). The number of foci of ICH again ranged from

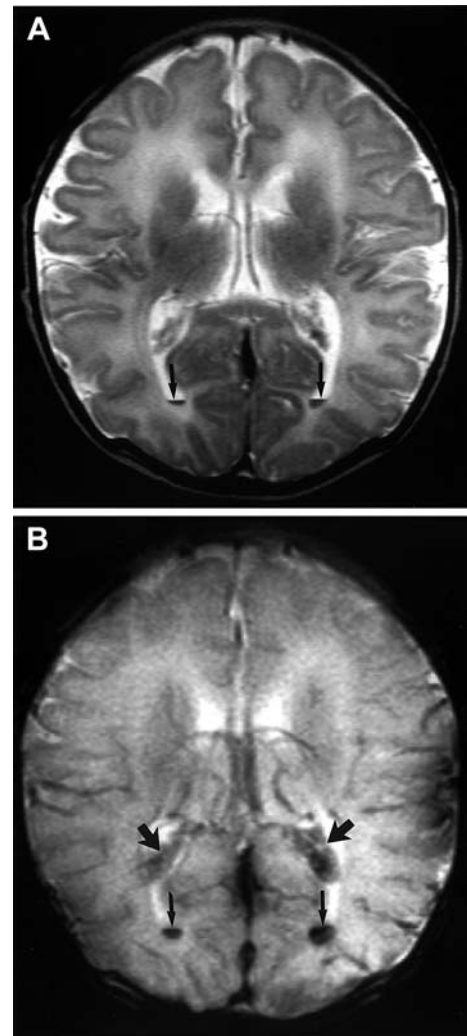


Fig. 2A, B Patient 13: choroid plexus and intraventricular hemorrhage. **A** Axial T2-weighted image shows small blood fluid levels (*arrows*) in both occipital horns. **B** Gradient-echo image shows loss of signal at sites of blood in occipital horns (*small arrows*) and bilateral choroid plexus (*larger arrows*)

none to three; there were 37 foci in the 23 patients (1.6 per patient). The amount of ICH had increased in 10 (48%) of the 23 patients, was unchanged in seven (30%) and smaller in six (26%). Of the 22 postoperative tentorial hemorrhages, 10 (45%) were new or larger, as were two (67%) of the three parenchymal hemorrhages. No neurologic signs were associated with any of these MRI findings. A comprehensive clinical description of these patients is found elsewhere [4].

Discussion

There are reports documenting hemorrhage attributed to the use of forceps or vacuum extraction [2, 5, 6, 7, 8,

Table 2 Postoperative studies

Patient	Neurological examination			Age at MRI (days)	Number of hemorrhagic lesions	Tentorial subdural hematoma	Supratentorial hematoma	Parenchymal hematoma	Choroid plexus bleed	Intraventricular bleed	Change from preoperative MRI
	Mental status	Tone in arms	Tone in legs								
1	Normal	Normal	Normal	21	2	1(unchanged)	1(unchanged)		New		None
2	Normal	Normal	Normal	9	3	New	New		1(unchanged)		Increased
3	Normal	Normal	Normal	10	2	1(unchanged)			1(unchanged)		None
4	N/A	N/A	N/A	11	2	1(unchanged)			1(unchanged)		None
5	Normal	Normal	Normal	23	3	1(smaller)	1(smaller)		1(unchanged)		Decreased
6	Normal	Normal	Normal	11	1	New					Increased
7	N/A	N/A	N/A	86	0						Decreased
8	Normal	Normal	Increased	8	2	1(smaller)	1(smaller)				Decreased
10	N/A	N/A	N/A	12	2				New		Increased
11	N/A	N/A	N/A	12	3	1(unchanged)			1(unchanged)		Increased
12	N/A	N/A	N/A	11	0						None
13	Normal	Normal	Normal	10	3	1(larger)			1(unchanged)		Increased
14	Normal	Normal	Normal	11	2	1(unchanged)			1(unchanged)		None
15	Normal	Normal	Normal	12	1	New					Increased
16	N/A	N/A	N/A	10	2	New					Decreased
17	Normal	Increased	Increased	14	0						Decreased
18	N/A	N/A	N/A	10	0						None
19	Normal	Normal	Normal	16	2	1(smaller)	1(smaller)				Decreased
20	Normal	Normal	Decreased	16	0						None
21	Normal	Normal	Decreased	7	1				New		Increased
22	Lethargic	Decreased	Decreased	15	2				New		Increased
23	N/A	N/A	N/A	16	3	New	New		1(larger)		Increased
24	Normal	Decreased	Normal	9	1	New					Increased

9]. Fetal and maternal factors that increase the risk of brain trauma have already been mentioned. The radiological findings reported [2, 11] were posterior cranial fossa subdural hematoma (tentorial and retrocerebellar), interhemispheric extra-axial hemorrhage, subarachnoid, intraventricular, and parenchymal bleeding. Parenchymal hemorrhage may especially be seen when birth is complicated by hypoxic-ischemic encephalopathy. The most vulnerable sites are the falcotentorial junction, around the incisura, and the petrous attachments of the tentorium [4].

The common explanation in the literature is that the stress induced by forceps or vacuum extraction places vertical traction on the skull and brain producing tentorial laceration, rupture of bridging veins in the subdural compartment, laceration of the venous sinuses or vein of Galen, or rupture of cortical veins. However, the incidence of subclinical intracranial hemorrhage in the term neonate after uncomplicated vaginal delivery is unknown. Holden et al. [12] described eight normal vaginally delivered infants: three had extra-axial hemorrhage along the falx cerebri and one had blood around the tentorial notch. They did

not report choroid plexus or intraventricular bleeding, as in this series. The small size of this study and the paucity of reports relating birth trauma with vaginal delivery are presumably due to the difficulty of obtaining consent from parents to allow their normal newborn children to undergo MRI. We focused our attention on children with CHD, who underwent MRI to detect ischemic lesions. We have shown that vaginal delivery is traumatic, in that it can be associated with asymptomatic intracranial hemorrhage. Tentorial tearing may result from pressure exerted on the molded skull of the baby during normal vaginal delivery. In the literature [5], as in our study, there is a predominance of bleeding in boys, possibly related to a larger head at birth. Our study indicates a good prognosis for birth hemorrhage in this population by virtue of their tendency to remain stable or improve, even after the stress and anticoagulation associated with heart surgery.

Acknowledgements Funding for the MRI studies was provided by Baxter Laboratories.

References

1. Koch TK, Jahnke SE, Edwards MSB, Davis SL (1985) Posterior fossa hemorrhage in term newborns. *Pediatr Neurol* 1: 96–99
2. Odita JC, Hebi S (1996) CT and MRI characteristics of intracranial hemorrhage complicating breech and vacuum delivery. *Pediatric Radiol* 26: 782–785
3. Clancy RR, McGaurn SA, Goin JE, et al (2001) Allopurinol neuro-cardiac protection trial in infants undergoing heart surgery using deep hypothermic circulatory arrest. *Pediatrics* 108: 61–70
4. Mahle WT, Tavani F, Zimmerman RA, et al (2002) An MRI study of neurological injury before and after congenital heart surgery. *Circulation* 106 [Suppl I]: 109–114
5. Huang CC, Shen EY (1991) Tentorial subdural hemorrhage in term newborns: ultrasonographic diagnosis and clinical correlate. *Pediatr Neurol* 7: 171–177
6. Serfontein GL, Rom S, Stein S (1980) Posterior fossa subdural hemorrhage in the newborn. *Pediatrics* 65: 40–43
7. Castillo M, Fordham LA (1995) MR of neurologically symptomatic newborns after vacuum extraction delivery. *AJNR* 16: 816–818
8. Hernansanz J, Muñoz F, Rodríguez O, Soler C, Principe C (1984) Subdural hematomas of the posterior fossa in normal-weight newborns. *J Neurosurg* 61: 972–974
9. Perrin RG, Rutka JT, Drake JM, et al (1997) Management and outcomes of posterior fossa subdural hematomas in neonates. *Neurosurgery* 40: 1190–1200
10. Hanigan WC, Morgan AM, Stahlberg LK, Hiller JI (1990) Tentorial hemorrhage associated with vacuum extraction. *Pediatrics* 85: 534–538
11. King SJ, Boothroyd AE (1998) Cranial trauma following birth in term infants. *Brit J Radiol* 71: 213–238
12. Holden KR, Titus MO, Van Tassel P (1999) Cranial magnetic resonance imaging examination of normal term neonates: a pilot study. *J Child Neurol* 14: 708–710